





N.T. Dzhaparaliev^{1*} , A.T. Zhusupova² ,
B.B. Kadyrova³ , B.B. Kulov² 

¹Kyrgyz State Medical Institute for Retraining and Advanced Training named after S.B. Daniyarova, Bishkek, Kyrgyzstan

²Kyrgyz State Medical Academy named after I.K. Akhunbaeva, Bishkek, Kyrgyzstan

³International School of Medicine of International University of Kyrgyzstan, Bishkek, Kyrgyzstan

*e-mail: dj-nurjan-t@mai.ru

(Received 19 January 2023; received in revised form 1 March 2023; accepted 3 April 2023)

A CASE REPORT OF RARE FAMILIAL DEMYELINATING DISEASE

Neuromyelitis optica or Devic's disease is an inflammatory disimmune-neurodegenerative disease characterized by a progressive course, predominantly affecting the optic nerves and spinal cord, with relatively intact brain structures. The differential diagnosis of neuromyelitis optica and multiple sclerosis is based on the identification of a typical clinical and tomographic picture and the presence of a high level of antibodies to aquaporin 4 in the blood serum. We presented a familial clinical case of Devic's disease in a representative of the indigenous population of Central Asia and the associated difficulties in differential diagnosis. M., 49 years old, was admitted to the Department of Neurology No. 1 of the National Hospital under the Ministry of Health of the Kyrgyz Republic with complaints on decreased vision and a feeling of a "veil" in front of the left eye, blindness on the right, weakness in all limbs, numbness in them, fatigue when walking, dizziness and instability when walking, a feeling of "passing an electric current". Thus, the onset of the disease in a 49-year-old patient was provoked by a hormonal imbalance – after a medical abortion due to a miscarriage, as well as after a viral infection (herpetic), symptoms of brainstem irritation were clinically presented, in particular .

Key words: demyelinating disease, neuromyelitis optica, multiple sclerosis, familial case, aquaporin-4.

Introduction

Neuromyelitis optica (NMO) is a severe inflammatory autoimmune disease of the nervous system, which manifests as a longitudinal widespread transverse myelitis and optic neuritis [1, 2]. This pathology is one of the orphan diseases, but it is more common among people of African and Asian origin. According to epidemiological studies in European countries, the prevalence of Devic's disease is 0.3–4.4 cases per 100,000 population [2, 3]. The woman of middle age (35–47 years) has higher prevalence (the ratio of women: men is approximately 2,8:1) [3]. Neuromyelitis optica is often misdiagnosed as multiple sclerosis (MS) [4], but the prognosis and treatment of these pathologies vary. However, the discovery in 2004 by V. Lennon et al. specific for this pathology serum antibodies to aquaporin-4 (neuromyelitis optica – Immunoglobulin G, NMO – IgG) suggested its independence. Aquaporin-4 is a complex protein that is obligately located on the astrocyte membrane [2, 5, 6]. It takes part in ensuring cell homeostasis by controlling the transport of water and salts through the cell wall.

The level of antibodies to aquaporin-4 correlates with disease activity and decreases with immunosuppressive therapy and remains low during remission.

The correlation of antibody titer with the severity of visual impairment, the size of lesions in the spinal cord, and the frequency of exacerbations was shown. Such antibodies are absent in patients with classical MS, in inflammatory and non-inflammatory diseases of the CNS, in other autoimmune diseases, and in healthy individuals [7, 8].

The clinical manifestations of NMO are optic neuritis and myelitis. Lesions of the optic nerves and spinal cord can sometimes occur simultaneously, but more often with a time interval that can be months, years, or even decades. Attacks of optic neuritis are often the first manifestation of the disease, preceding myelitis [9, 10]. Ophthalmoscopy often reveals a normal fundus picture, slight opacity of the optic discs, and there may also be mild edema, atrophy, and pallor of the optic discs in chronic cases. Spinal cord injury is characterized by acute partial transverse or longitudinal widespread myelitis. More often, the cervical and thoracic sections of the spinal cord are involved in the pathological process [11, 12]. Typical symptoms of myelitis are muscle weakness, spasticity, loss of coordination, ataxia, Lhermitte's symptom, urinary retention, autonomic dysfunction [13]. In most cases, patients after an attack of myelitis have a partial recovery of motor functions, but complete regression is not typical. NMO is also characterized by damage to

the circumventricular organs, manifested by uncontrollable nausea and vomiting (area postrema and the floor of the fourth ventricle), hiccups, inappropriate antidiuretic hormone secretion syndrome, narcolepsy or anorexia (hypothalamus), or posterior pituitary endocrinopathy [14]. Damage to the brain stem is affected in 31% of cases (vomiting, hiccups, oculomotor disorders, itching, hearing loss, facial paralysis, vestibulopathy, trigeminal neuralgia) [1, 3, 15].

Combined damage to the spinal cord and optic nerves can also be observed in other diseases, such as multiple sclerosis, systemic autoimmune diseases, which makes diagnosis difficult. One of the main diagnostic methods is MRI of the brain and spinal cord.

The possibility of linking demyelinating diseases with genetic factors has constantly attracted the attention of researchers. Foreign authors revealed a high concordance in monozygotic twins with multiple sclerosis, described families in which two or more cases of the disease were observed, which once again proves the role of hereditary factors in the development of the disease [3, 5]. Unfortunately, only a few familial cases of Devic's disease is described in the literature, and the role of genetic factors in the development of NMO is little studied. Although most cases of neuromyelitis optica are sporadic, rare cases of familial seropositive AQP4-IgG NMO with a classic phenotype indicate a genetic predisposition. Given the rare occurrence of a familial case of neuromyelitis optica in the population, we present a rare clinical observation of a familial case.

Materials and Methods

M., 49 years old, was admitted to the Department of Neurology No. 1 of the National Hospital under the Ministry of Health of the Kyrgyz Republic with complaints on decreased vision and a feeling of a "veil" in front of the left eye, blindness on the right, weakness in all limbs, numbness in them, fatigue when walking, dizziness and instability when walking, a feeling of "passing an electric current" along the spine and limbs when tilting the head, urinary and fecal retention.

The onset of the disease at the age of 44y.o., after a medical abortion due to a missed pregnancy at 12 gestation weeks, she developed nausea. After 2 weeks, vomiting joined, lasting up to 4 months. Repeatedly underwent examination and treatment at the therapist and the gastroenterologist. There was no effect from the therapy. She was re-examined by a gynecologist – no pathology was detected during the examination. The patient also notes that before that, herpetic eruptions on the inner surface of the thighs and perineum were observed almost monthly. She

was applying on rashes topical antiviral ointments (acyclovir). Subsequently, vomiting regressed, however, there was a deterioration in the form of weakness and limitation of movements in the right leg and left arm, which slowly progressed. Received a course of acupuncture which was without effect. Subsequently, a week later, the patient's condition suddenly worsened – all limbs weakened, pelvic organ's dysfunction by central type joined in the form of retention of urine and feces. She was hospitalized in the Department of Neurology No. 3 from 09/22/15 to 10/09/15 with diagnosis of upper spinal myelitis with tetraparesis, rougher on the left and partial spastic dysfunction of the pelvic organs. An MRI examination of the head cervical spine revealed data for acute myelitis of the cervical region and visualized thoracic spinal cord, straightness of lordosis, moderately pronounced left-sided cervicothoracic scoliosis, pituitary adenoma is not excluded. Against the background of pulse therapy with methylprednisolone, there was an improvement in the condition in the form of an increase in muscle strength in the limbs, she began to walk with outside support, and pelvic disorders regressed. Subsequently, the patient was actively involved in neurorehabilitation at a private medical center, movements in the limbs recovered to mild tetraparesis. The subsequent exacerbation was noted on June 27, 2020, when, against the background of a coronavirus infection with general infectious manifestations, there was a sharp decrease in vision in the right eye, pain when moving the eyeballs and general weakness. Subsequently, visual disturbances on the right eye progressed to complete blindness and a decrease in vision in the left eye was added. She received treatment from an ophthalmologist at the place of residence – dexamethasone was administered. On the background of treatment by an ophthalmologist, the patient's condition improved in the form of improved vision in the left eye. The last deterioration in the condition since August 25, 2020, when weakness and limitation of movements in all limbs, retention of urine and feces began to bother, headaches appeared, mainly left-sided localization, pain in the eyes, aggravated when looking to the side, a feeling of «passage of electric current» along the way spine and legs with head tilt, general weakness, fatigue, and therefore hospitalized in this department to clarify the diagnosis and course of inpatient treatment.

General somatic status without features

In neurological status: conscious, oriented in place, time and self. Meningeal signs are not defined.

Eye fissures D = S. Pupils are rounded, D = S, photo-reactions are alive. Amaurosis on the right, amblyopia on the left. Afferent pupillary defect on the right. There is no visual field loss. The movements of the eyeballs are in full, painless. Horizontal mounting nystagmus. The face is symmetrical, the tongue is in the midline. Swallowing is not disturbed; the pharyngeal reflex is evoked. Tendon reflexes are high, D = S. Positive pathological hand and foot reflexes are determined – bilateral symptoms of Jacobson-Lask, Rossolimo, Oppenheim and Babinsky. Muscle tone is increased in the legs according to the spastic type. Muscle strength is reduced in all limbs to 3 points. There is no atrophy. Conductive type of hypoesthesia from level of C4. Coordinator tests – finger nose test performs with a miss. Staggering in the Romberg position. The functions of the pelvic organs are impaired by the central type.

Passed examinations from 09/04/20:

- General and biochemical blood tests: indicators are within the normal range
- Chest x-ray: no features
- ECG: sinus rhythm, heart rate 61, normal position of the EAH
- ELISA for coronavirus: IgG 4.1, IgM 0.39
- Antibodies to aquaporin-4: 1:160

- Antinuclear antibodies (anti – Sm, RNP, SS-A, SS-B, Scl-70, PM- Scl , PCNA, CENT-B, Jo-1, to histones, to nucleosomes , Ribo P, AMA-M2): negative .
- Anti-phospholipid antibodies IgM / IgG: negative.
- Rheumatic tests: RF negative, ASLO 200, CRP negative.
- CMV IgG: 1:800
- Herpes I + II type IgG: 1:40
- ELISA IgG Epstein- Barr virus: negative.
- Ophthalmologist: Atrophy of the optic nerves
- MRI of the brain and cervical spine dated on September 6, 2020 are shown in Figures 1 and 2.

The patient was diagnosed with a clinical diagnosis of “Devic’s disease (NMO) with visual impairment, moderate central tetraparesis, and dysfunction of the pelvic organs by central type. Relapsing-remitting type, phase of exacerbation. EDSS 4.5 points”.

Treatment was carried out: Solumedrol 1000 mg intravenously for 5 days, followed by transfer to medrol 64 mg/ day orally, then dose reduction according to the scheme, potassium and magnesium preparations 1 tab 3 times, calcium preparations 1 tab 1 time, omeprazole 20 mg 1 tab 1 time, azathioprine 50 mg 1 tab 3 times.

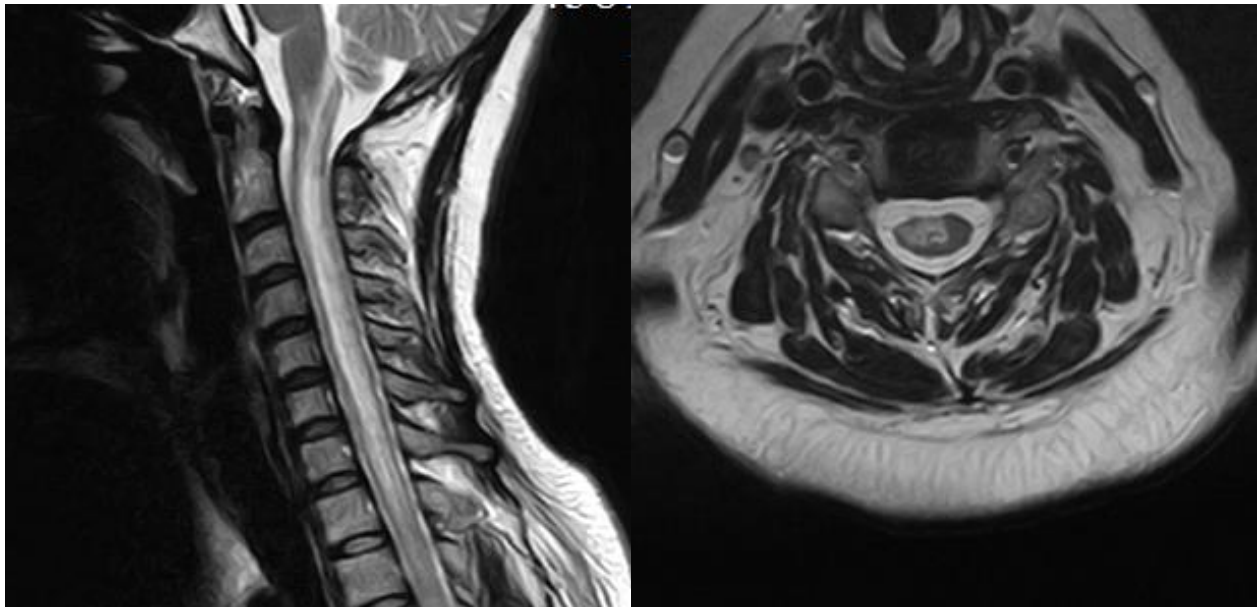


Figure 1 – T2-weighted images in the sagittal and frontal planes: in the spinal cord at the level of all cervical and visualized thoracic vertebrae, a focus of pathological signal enhancement is visualized, an elongated shape, 76x8x4 mm in size. There is slight annular enhancement on post-contrast tomograms.

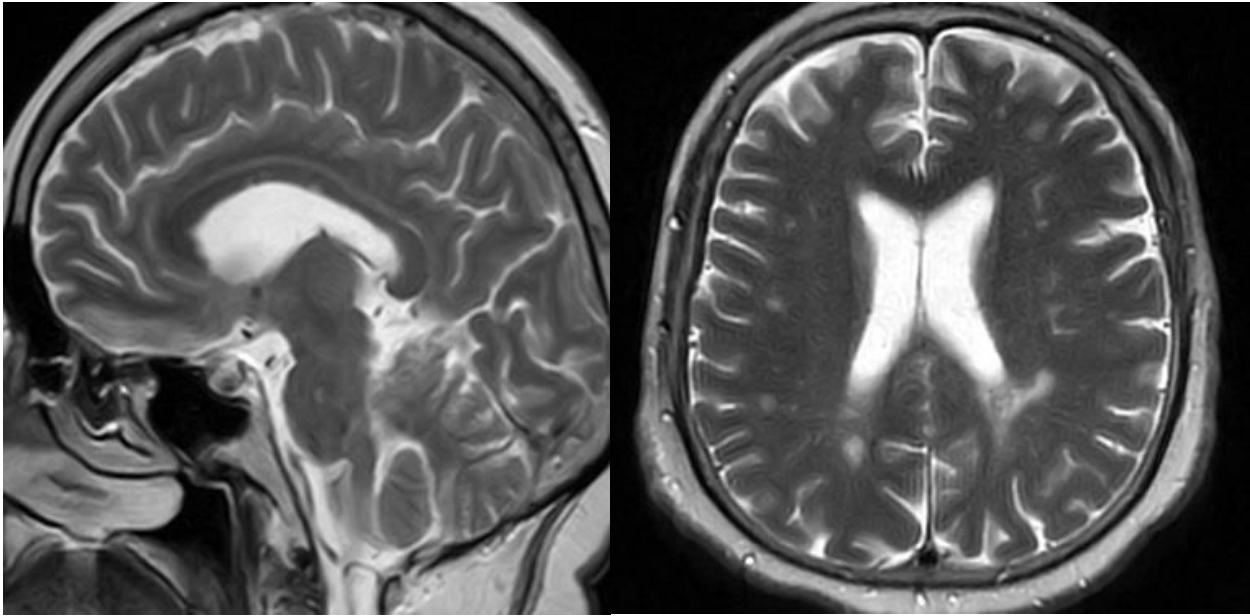


Figure 2 – MRI in the sagittal and frontal planes revealed data for a focus of pathological MR signal intensity in the parenchyma of the medulla oblongata; single foci of glial changes in the parenchyma of the frontal and parietal lobes of the cerebral hemispheres. Initial manifestations of dyscirculatory encephalopathy.

Against the background of the therapy, there was a positive trend in the patient's condition: improved vision in the left eye, increased muscle strength in the limbs, urge to urinate and defecate, decreased numbness of the limbs.

Patient I. (mother of patient M), born in 1942, was previously hospitalized in this department. According to the medical history of her mother provided from the archive, the patient was hospitalized in the Department of Neurology No. 1 from 10/16/2000 to 10/30/2000 with a clinical diagnosis of «Progressive spinal ischemic stroke in the basis of the radicular-spinal arteries of the cervical and thoracic spinal cord with mixed tetraparesis (flaccid paresis in the arms, spastic in the legs) and dysfunction of the pelvic organs by central type. Atherosclerosis of cerebral and spinal vessels». Analyzing the life history data from the medical history, the onset was sudden on July 20 of 2000, with a feeling of numbness in the left leg, followed by numbness of the right leg, weakness and limitation of movement in the legs and urinary retention a week later. Upon admission to the hospital, the results of general clinical and biochemical analyzes were within the normal range. A lumbar puncture was performed, CSF – slightly xanthochromic color, protein 0.33 g, Pandi +, Cytosis 8/3, lymphocytes. An MRI of the spine revealed an intramedullary formation at the level of Th6 – Th9, which must be differentiated from a mass formation and a hematoma. Protrusion of the C5-C6 discs, posterior protrusion of the L4 – L5 discs. On MRI of

the brain – manifestations of dyscirculatory encephalopathy, demyelination phenomena, mixed hydrocephalus. The patient at that time was examined by a neurosurgeon, who ruled out mass formation. At the hospital, the patient received a course of vascular metabolic therapy, against which the patient's condition did not improve. According to her daughter, after being discharged from the hospital, her mother's condition worsened 2 months later in the form of soreness in the eyes when looking to the side, a pronounced decrease in vision, to blindness on the right. She was hospitalized at the place of residence, against the background of hormone therapy, the patient's condition improved in the form of improved vision. Didn't provide a statement. The subsequent exacerbation was noted a year later, when after the acute respiratory viral infection, the symptoms of the disease progressed – weakness in the limbs increased, she became blind in both eyes, with the addition of respiratory failure two days later. The patient was hospitalized in the intensive care unit at the place of residence, but despite the treatment, the patient died on the background of acute neurogenic respiratory failure.

Results and Discussion

Thus, the onset of the disease in a 49-year-old patient was provoked by a hormonal imbalance – after a medical abortion due to a miscarriage, as well as after a viral infection (herpetic), symptoms of brain-

stem irritation were clinically presented, in particular “area postrema” in the form of prolonged vomiting, nausea. After the examination by a therapist there was revealed no pathology, which excluded the symptoms of a gastrogenous nature. Subsequently, there were symptoms of lesions of the optic nerve and the upper cervical spinal cord in the form of symptoms of damage to the pyramidal system – tetraparesis, sensory lesions by segmental and conductive type loss of sensitivity, in combination with pelvic disorders of the central type. The above episode of the stem and optic-spinal symptom complex, followed by an incomplete reduction of neurological symptoms, the onset and nature of exacerbation, without multiple foci of demyelination in the brain, is less likely to correspond to multiple sclerosis. Identification of a typical spinal focus, such as transverse myelitis, which, according to MRI of the spinal cord, spread classically – longitudinally, to more than 3 segments, as well as high titers of antibodies to aquaporin-4 (1:160) made it possible to make a clinical diagnosis of Neuromyelitis optica. Taking into account the negative results of the spectrum of antinuclear antibodies in this patient, markers of systemic diseases

of the connective tissue, diseases of the spectrum of myelitis optic-associated disorders are excluded.

From her mother’s medical history, it can be concluded that the patient was less likely to have a progressive spinal stroke, since the neurological symptoms described above were recurrent in nature, i.e. with clear periods of exacerbation and remission with incomplete reduction of symptoms, subsequent addition of symptoms of damage to the optic nerve, without any special changes on MRI of the brain, but with the presence of a focus on MRI of the thoracic region (more frequent localization in NMO). There is no doubt that the above-described optic-spinal symptoms in the patient’s mother are associated with the presence of “Devic’s disease, neuromyelitis optica”, even if the patient does not have test results for specific antibodies to aquaporin-4. When analyzing two clinical rare cases in a mother and her daughter, a hereditary predisposition for this disease is clearly traced. A feature of these clinical cases is the incorrect diagnosis of the patient’s mother and, accordingly, the absence of pathogenetic treatment. Therefore, in order to ensure early detection and slow down disability in opticomyelitis, it is necessary to increase the alertness of practitioners regarding this pathology.

References

1. Derevyannykh E.A., Shepilova I.D., Karamysheva K.N., Sukhanova M.A., Khamidulina A.M., Molchanova N.S. Devic’s disease (optocomyelitis): a clinical case and a review of the literature // Vestnik SMUS74. 2016. No. 3 (14).
2. Shishkina E.S., Mukhacheva M.V., Renzina T.V. Optocomyelitis (Devic’s disease): a case report // Vyatka Medical Bulletin. 2019. No. 1 (61).
3. N.YU. Gorokhova, T.YA. Nikolayeva, T.Ye. Popova, L.T. Okoneshnikova optikoneyromiyelit: klinicheskoye nablyudeniye. (Opticoneuromyelitis: clinical observation) Vestnik Severo-Vostochnogo Federal’nogo Universiteta Imeni M.K. Ammosova DOI 10.25587/SVFU.2018.3(13).20040
4. Schneider E., Zimmermann H., Oberwahrenbrock T. et al. Differences in optica neuritis related retinal damage between patients with neuromyelitis optica and multiple sclerosis. MSJ. 2019; 8 (Suppl. 4): 69.
5. Huda S, Whittam D, Bhojak M, Chamberlain J, Noonan C, Jacob A. Neuromyelitis optica spectrum disorders. Clin Med (Lond). 2019 Mar;19(2):169-176.
6. Paul F., Jarius S., Aktas O. et al. Antibody to aquaporin-4 in the diagnosis of neuromyelitis optica. PLoS Med. 2007; 4: 0669–73.
7. Trebst C, Jarius S, Berthele A, Paul F, Schippling S, Wildemann B, Borisow N, Kleiter I, Aktas O, Kümpfel T. Neuromyelitis Optica Study Group (NEMOS): Update on the diagnosis and treatment of neuromyelitis optica: recommendations of the Neuromyelitis Optica Study Group (NEMOS). J Neurol. 2014; 261:1-16.
8. Carnero Contentti, E., Correale, J. Neuromyelitis optica spectrum disorders: from pathophysiology to therapeutic strategies. J Neuroinflammation 18, 208 (2021).
9. Lucchinetti CF, Guo Y, Popescu BF, Fujihara K, Itoyama Y, Misu T. The pathology of an autoimmune astrocytopathy: lessons learned from neuromyelitis optica. Brain Pathol 2014; 24:83-97.
10. Awad A., Stüve O. Idiopathic transverse myelitis and neuromyelitis optica: Clinical profile, pathophysiology and therapeutic choices. Curr. Neuropharmacol. 2011; 9(3): 417–28.
11. Weiss D, Cantré D, Zettl UK, Storch A, Prudlo J. Lethal form of a late-onset aquaporin-4 antibody-positive NMOSD related to the immune checkpoint inhibitor nivolumab. J Neurol 2022; 269:2778-2780.
12. Papp V, Magyari M, Aktas O, et al. Worldwide incidence and prevalence of neuromyelitis optica: a systematic review. Neurology 2021; 96:59-77.
13. Trebst C., Raab P., Voss E. et al. Longitudinally extensive transverse myelitis – it is not all neuromyelitis optica. Nat. Rev. Neurol. 2011; 7: 688–98.]
14. Poppe A., Lapierre Y., Melanc D. et al. Neuromyelitis optica with hypothalamic involvement. MSJ. 2015; 11: 617–21.]
15. Asgari N., Skejoe H., Lillevang S. et al. Modification of longitudinally extensive transverse myelitis and brainstem lesions in the case of NMO. BMC Neurol. 2013; 13: 33